

## EFFECT OF RADIATION ON THE NAIL TISSUE (PART II)

BY

Tadashi ADACHI and Kazuhisa HARUYAMA\*

### ABSTRACT

This experiment is directed to study the chronic radiation injury of nail.

The ridging of nail plate in chronic radiation damage of nail may be caused by the combination of radiation injury to the nail matrix, hyponychium and nail lamellae.

Fragility may be resulted from frequent interruption of mitosis in nail matrix.

The thickening of nail plate was not remarkably observed in this experiment. The thickening of nail plate reported in man associated with chronic radiation damage to nail can be explained by slowing down of forward movement of nail plate, incompleteness of successive cell differentiation and coarseness of nail plate.

In other words, various changes of nail reported as a chronic radiation injury of nail in man<sup>2-4)</sup> seem to be ones in the fractionated irradiation in the experimental animal.

### INTRODUCTION

In the previous paper<sup>1)</sup>, we mainly dealt with injuries of nail produced by high dose irradiation to clarify the mechanism of nail changes.

However, the changes of nail plate produced by single or fractionated irradiation ( $5 \times 10$ ) were slight, so that this experiment is directed to study the chronic radiation injury (fragility, thickening, etc.) of nail.

### METHOD

The method of the present experiment is the same as one in the previous paper, except for the dose of exposure. A total dose of 8000 R were irradiated to both hind legs of Wister rats. The dose of irradiation was fractionated into 125 R every other day  $\times$  64 during a period of 3.5 month and then the irradiated toes were amputated for the histological investigation. Exposure dose of 8000 R is corresponding to a single irradiation of

\* 足立 忠, 春山和久: Department of Radiology (Chief: Prof. T. ADACHI), School of Medicine, Tokyo Medical and Dental University (Tokyo Ika Shika Daigaku).

Received for publication, December 9, 1967.

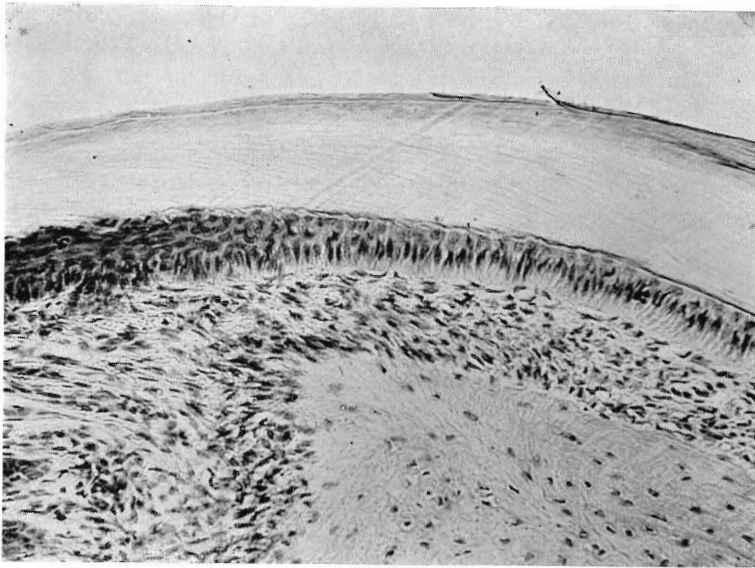


Fig. 1. Cross section of normal (non irradiated) digid ( $\times 200$ ).

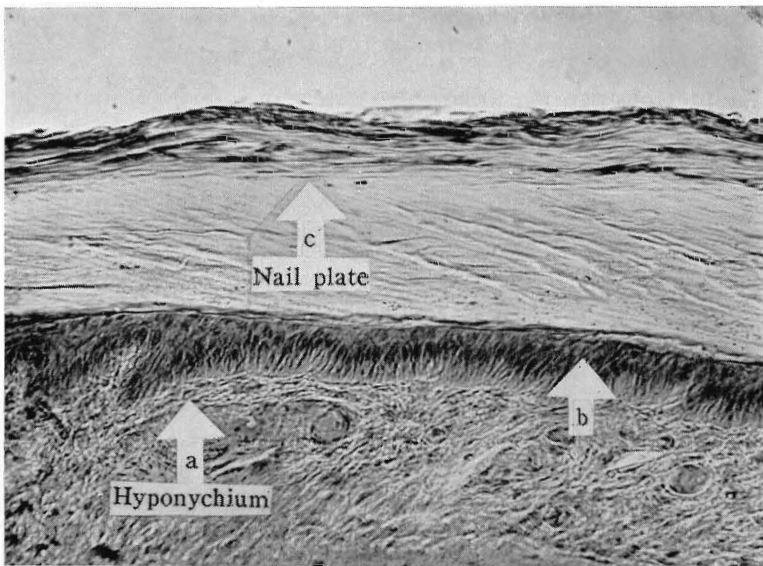


Fig. 2. Cross section of irradiated digid ( $\times 200$ ).  
a: Cylindrical cell layer, b: Cuboid cell layer,  
c: Separation of nail lamellae.

2000 R, based upon the recovery index of nail tissues.

### RESULTS

**Nail matrix:** Irregularity of basal cell layer and decrease of mitotic cell number are observed. The above findings are similar to the groups of fractionated irradiation in the previous paper.

**Hyponychium:** The alignment of each of two epithelial layers of hyponychium is uneven, especially in the cylindrical layer (Fig. 2, a). On the other hand, outer layer of cuboid epithelial cells becomes polymorphic in shape (Fig. 2, b). As a result of those changes, the surface of nail bed, bordered on the ventral surface of nail plate, become uneven.

**Nail plate:** Deformity of nail plate, especially its dorsal layer, and separation of nail lamellae are observed (Fig. 2, c). The above changes may be responsible for the ridging and fragility of nail plate recognized in man.

**Other changes:** Changes of hair, skin, bone and other paraungual tissues are slight.

### REFERENCES

- 1) Adachi, T. and Haruyama, K.: Effect of radiation on the nail tissue. Bull. Tokyo Med. Dent. Univ., 13: 369-379, 1966.
- 2) Rajewsky, B.: Jadassohn's Handb. d. Haut- und Geschlechtskrankheiten. Springer-Verlag, Berlin, V/2, 151-152, 1959.
- 3) Heller, J.: Jadassohn's Handb. d. Haut- und Geschlechtskrankheiten. Springer-Verlag, Berlin, VIII/2, 31, 1927.
- 4) Epstein, E.: Radiodermatitis. Charles & Thomas Publisher, 1962. pp.40-53.